

Glenoid Exposure in Shoulder Arthroplasty

Patrick Birmingham, MD,* John W. Sperling, MD, MBA,† and Edward Craig, MD, MPH‡

Abstract: Glenoid exposure is a critical step in total shoulder arthroplasty. Earlier surgery, contractures, and asymmetric wear are just a few of the things that need to be recognized and planned for preoperative evaluation. Good exposure begins with meticulous positioning and hinges on carrying out adequate releases and bony cuts. The purpose of this review is to describe the various steps and techniques necessary to achieve good glenoid exposure during total shoulder arthroplasty.

Key Words: total shoulder arthroplasty, glenoid exposure, glenoid resurfacing, osteoarthritis

(*Tech Should Surg* 2010;11: 92–96)

Total shoulder arthroplasty is a successful operation with a survival rate of 87% at 15 years.¹ The complication rate is approximately 16%, with the most common complications being glenoid loosening, glenohumeral instability, rotator cuff tear, fracture, and infection.² Indications for resurfacing the glenoid are controversial, but include improved pain over hemiarthroplasty, increased stability in the setting of glenoid wear, and lateralization of the joint line potentially improving the range of motion and strength.^{3–6} The glenoid component failure rate had been reported to be as high as 12.5%; however, revision for glenoid loosening averages 5.6%.^{7,8} Contraindications for glenoid resurfacing are also controversial, but include a dysfunctional rotator cuff, which can lead to eccentric superior loading of the component or the so-called “rocking horse glenoid” and possible early loosening; a dysfunctional deltoid; young active patients; or inadequate glenoid bone stock.^{9–11} In the setting of bone deficiency greater than 30%, the glenoid can be bone grafted, most commonly with the cut humeral head, before component placement.¹² The glenoid bone stock should be evaluated preoperatively with high-quality axillary radiographs for asymmetric wear and 30-degree external oblique “true” anteroposterior radiographs for inferior and superior bone stock.¹³ Computed tomography scans may also be helpful in determining the version of the glenoid and the specific glenoid wear pattern (Fig. 1). Three-dimensional computed tomography scans are very helpful in posttraumatic cases in which there is significant distortion of the anatomy.

Some key steps to successful glenoid resurfacing are adequate contracture releases, rebalancing of the soft tissues, and accurate component placement,^{4,14,15} and all of these require superb glenoid exposure. In addition, the set-up for adequate glenoid exposure begins before the skin is incised. These steps include satisfactory muscle relaxation with adequate anesthesia, patient and arm positioning, stabilization of the scapula during positioning, and draping allowing for access to the entire upper quadrant.

From the *Department of Orthopaedic Surgery, Medical College of Wisconsin, Milwaukee, WI; †Department of Orthopaedic Surgery, Mayo Clinic, Rochester, MN; and ‡Department of Orthopaedic Surgery, Sports Medicine Division, Hospital for Special Surgery, New York, NY.
Reprints: Edward Craig, MD, MPH, Sports Medicine Division, Hospital for Special Surgery, 535 East 70th Street, New York, NY 10021 (e-mail: craige@hss.edu).

Copyright © 2010 by Lippincott Williams & Wilkins

PERIOPERATIVE CARE

A preoperative range-of-motion examination is carried out to evaluate any current limitations in motion, as excessive tightness can limit exposure and requires soft tissue releases. A limitation in external rotation, as compared with the contralateral side, is a good indicator of how extensive subscapularis mobilization will need to be.¹⁶ In addition, severe posterior glenoid wear can be inferred posteriorly by fullness. This can result in significant relative retroversion of the glenoid, and will make exposure to the glenoid face much more difficult. In these cases, significant capsular releases are essential for adequate glenoid exposure. Either regional interscalene block or general anesthesia is sufficient. However, in a tight shoulder, high muscle tension in the pectoralis major muscle can make the exposure of the glenohumeral joint very difficult. Thus, although interscalene blocks allow for quicker recovery and improved pain relief in the immediate postoperative period, intraoperatively, the patient cannot be completely paralyzed unless they are additionally intubated. There is also a low incidence of persistent paresthesias associated with interscalene blocks as well.^{17–19}

The patient is then positioned with the head of the bed elevated to 30 to 45 degrees, and with the patient laterally on the bed far enough so the arm can be extended behind the torso, but also so that the scapula can be secure. The knees should be in a flexed position to prevent any traction on the sciatic nerve. To support the arm, an arm board can be placed on the table in the parallel position, with its most proximal extent at the level of the distal biceps insertion. The ability to position the arm intraoperatively is critical for exposure. For preparation of the humerus, the arm must be able to be hyperextended off the side of the table. For exposure and preparation of the glenoid, it is essential that the humerus, after head

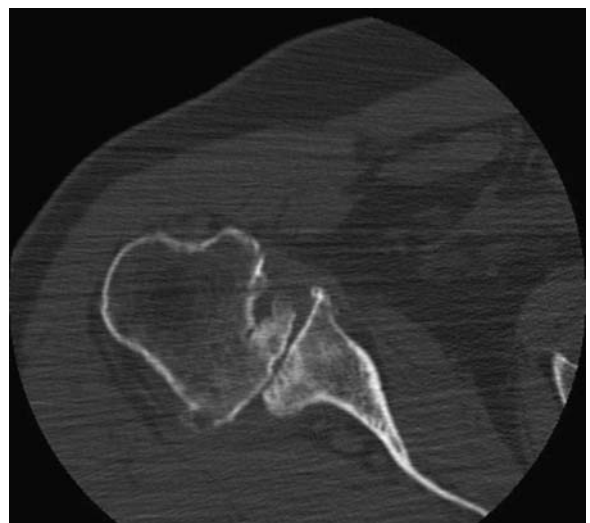


FIGURE 1. Typical example of posterior glenoid wear and posterior humeral subluxation seen in osteoarthritis of the shoulder.

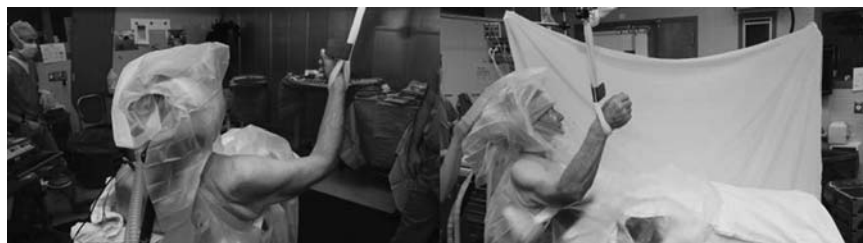

FIGURE 2. Patient positioning for a shoulder arthroplasty. Note that the entire medial border of the scapula is free to help facilitate proper exposure at the time of surgery.

resection, be retracted posterior to the glenoid face. Although other steps and releases are important, arm support of the humerus permits the humerus to be retracted posterior to the glenoid face. Other options are to use a padded Mayo stand or an industrial arm holder. The patient's head can either be placed in an attached holder or held with a molded beanbag (Fig. 2).

After sterile preparation, draping should include 2 "U" drapes to allow full extension, abduction, and external rotation of the arm. An adhesive-backed, iodine-impregnated type drape can be used to seal off the axilla and surgical field. The entire extremity including the chest, upper quadrant, and the entire scapula should be prepped and draped in the field.

TECHNIQUE

Deltopectoral Approach

The skin incision for the long deltopectoral interval starts at the midpoint between the coracoid process and the antero-lateral acromion and proceeds in a distal and lateral direction ending just lateral to the biceps at the deltoid insertion. An alternative approach is to use the anterior-superior approach, which uses an incision that starts posterior to the acromioclavicular joint and proceeds distally and laterally. This approach involves taking down some of the anterior origin of the deltoid, and proceeds through the rotator interval. For the deltopectoral approach, once the dermis is incised, sharp rakes can be used to retract the skin, and electrocautery is used to dissect down to the fascia covering the deltopectoral interval. The fat stripe covering the cephalic vein should be found and grasped proximally, as a metzenbaum scissor or a cautery is used to unroof the entire vein in the field (Fig. 3). The vein can then either be completely excised, by using a suture ligature to tie off its most proximal and distal extents, taken laterally with the deltoid, or medially. There are more perforating veins heading laterally to the deltoid, therefore it is easier to maintain hemostasis in this manner; however, there is a risk of injuring

the vein from retraction. In the setting of rheumatoid arthritis, however, the vein is taken medially because it is easier to mobilize this way in this setting. The interval can be further developed with finger dissection, and the superior edge of the pectoralis major should be located. The pectoralis major fibers may be differentiated from the deltoid by their differing orientation.¹⁶ Mobilization of the subdeltoid space is an essential step for all total shoulder exposures. Freeing the planes between the deltoid, subdeltoid, and subacromial is to be carried out bluntly. In rheumatoid arthritis, retracting the muscle can traumatize and cut fibers because the tissue is extremely friable. To take some tension off the deltoid muscle, some of the broad tendinous deltoid extensions to the lateral humerus can be released with the electrocautery. A self-retaining or 2 Richardson retractors can then be used to hold open the interval. In a tight shoulder, the superior border of the pectoralis major can be released approximately 1 cm or about 20% of the proximal-distal width. The claviopectoral fascia lateral to the conjoint tendon should then be incised, and the conjoint tendon retracted medially, careful not to injure the musculocutaneous nerve. The inferior border of the subscapularis should then be palpated to locate the axillary nerve, the "tug test." The coracoacromial ligament is then released, and an elevator or the finger can be used to release any subacromial bursal adhesions. In shoulders that are previously operated on and posttraumatic arthritis, the adhesions in the subacromial space can be significant. Complete separation of the deltoid muscle from the cuff is essential.

Subscapularis Division and Glenohumeral Joint Exposure

The arm is then externally rotated, which increases the distance between the axillary nerve and the subscapularis,¹⁶ and adducted, which puts the subscapularis on a stretch, so that the anterior circumflex humeral artery and its venae comitantes "3 sisters" can be located at the inferior border of the muscle. The vessels are either tied off as a unit with suture ligature or

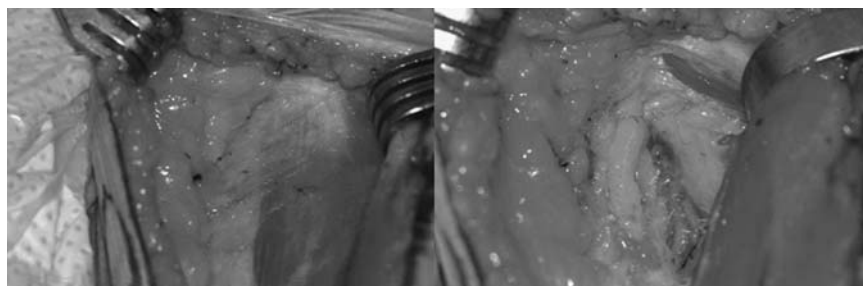


FIGURE 3. The deltopectoral interval may be found proximally. Typically, there is a triangle of fat present between the deltoid and pectoralis major.



FIGURE 4. The labrum is meticulously removed from the glenoid to expose the true glenoid bone anatomy.

cauterized. The subscapularis and anterior capsule are then taken down together approximately 1 to 2 cm medial to the lesser tuberosity. Alternatively, the tendon can be taken directly off the lesser tuberosity with or without a wafer of bone. Several Number 2 ethibond tagging sutures are placed medially in the tendon serially from superior to inferior as it is released. The rotator interval and coracohumeral ligament are then released back to the base of the coracoid. The most inferior part of the subscapularis is predominantly muscle fibers. It is essential for the complete release of the subscapularis, so that the humerus can be adequately retracted posteriorly for glenoid exposure. Bleeding can sometimes be troublesome as the anterior humeral circumflex vessels are cauterized; however, they are important markers of the inferior border of the subscapularis. The axillary nerve is a few millimeters medial to the musculotendinous junction of the subscapularis, so that external rotation combined with blunt retraction between the subscapularis and axillary nerve permits both the muscle and capsule to be divided safely under direct visualization. An elevator or a flat Darrah-type retractor is then placed inferiorly to protect the axillary nerve whereas the inferior capsule is cut to at least the 6 o'clock position. This dissection is taken on the humeral neck medially to the biceps and inferior to the subscapularis.²⁰ The difficulty with glenoid exposure is usually directly related to insufficient capsular release. In most difficult cases, the capsule may need to be released circumferentially. It is critical to know the location of the axillary nerve and to protect it throughout the exposure.

Exposing the Glenoid

The humeral head is then dislocated by bringing the arm into extension, adduction, and external rotation, and all of the head osteophytes are removed; this effectively lengthens the capsule.²⁰ Dislocation may be aided by placing a blunt retractor behind the humeral head and under the rotator cuff. The humeral head cut is then made, making sure the blade

exits directly at the level of the rotator cuff attachment to the inner portion of the tuberosity. If the cut is not made at the tendon insertion, too much of the humeral head may remain. This can block glenoid exposure. However, the outcome may be compromised if the cut is made into the rotator cuff or the greater tuberosity. The exact angle and position of the humeral head cut are dependent on the total shoulder system used, and may be made with intramedullary or extramedullary guides. Care must be taken to remove any inferior-medial osteophytes, as these may act to block glenoid exposure. A metaphyseal cap may then be placed to protect the bone at the head cut during retraction for glenoid exposure. The position of the arm and the retraction of the humerus, deltoid, and subscapularis from the surgical field are crucial for glenoid exposure. The arm is then placed at 30 degrees of abduction and neutral rotation.²⁰ A Fukuda ring type or a 2-pronged retractor is then placed behind the posterior glenoid to retract the humerus. If the humerus cannot be adequately displaced posteriorly, more posterior capsule can be released.¹⁶ The arm can be rested either on an arm board or padded mayo, or held with an arm holder. At this point, if the decision is made to proceed with glenoid replacement, the junction of the anterior glenoid rim and the capsulolabrous junction is incised with a knife, and a spiked glenoid retractor is placed on the anterior glenoid. A retractor is also placed on the posterior glenoid, and a medium-sized flat/Darrah retractor can be placed superiorly in the subacromial space behind and above the biceps insertion for retraction as well. The placement of these retractors gives good visualization of the glenoid face. Retractors around the glenoid should be meticulously placed and should stay directly on the glenoid bone to avoid injury to the axillary nerve, which travels around the inferior aspect of the glenoid from anterior to posterior. The glenoid labrum, both anteriorly and posteriorly, can be excised with any overhanging soft tissue (Fig. 4). This gives maximal access to the glenoid bone for analysis of the wear pattern. In addition, if exposure is still difficult, the inferior and posterior capsules can be further released. However, if the

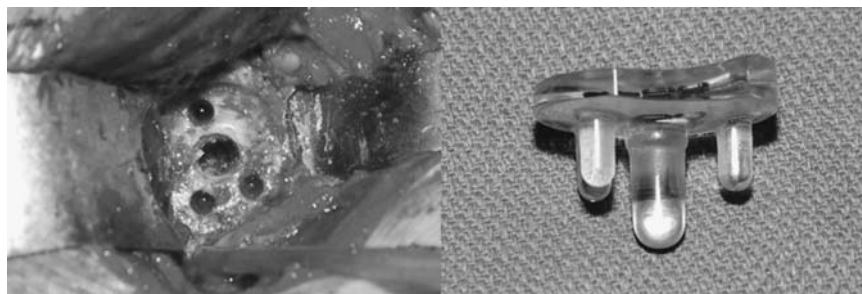


FIGURE 5. The glenoid may be prepared to accept a keeled or pegged option based on surgeon preference.

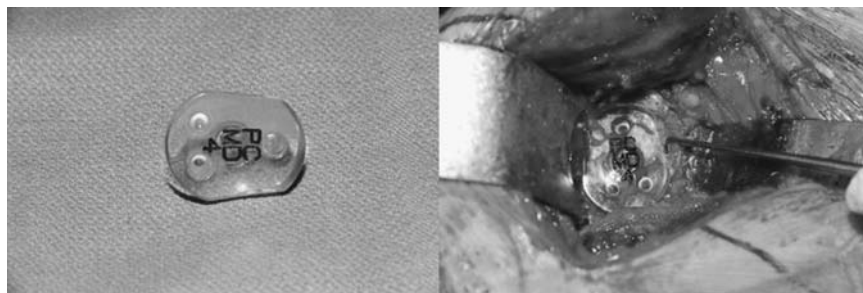


FIGURE 6. One should be sure that the trial component is down securely on the glenoid faceplate.

patient has a history of posterior instability, the capsule is likely stretched out and the further release will not aid in exposure, and could possibly lead to postoperative instability. If the posterior rim of the glenoid is asymmetrically eroded producing increased retroversion, the anterior rim can be burred and planed down to reduce the amount of retroversion to an acceptable amount. The average glenoid is retroverted approximately 1 to 2 degrees with respect to the scapula, therefore selective anterior reaming should use this as the goal as long as there is adequate glenoid bone stock. If the posterior erosion is severe, the glenoid may have to be bone grafted. In either case, glenoid reamers are used to normalize the version and to smooth the surface. The largest-sized component, which allows no overhang, is chosen. A pegged or keeled component is then trialed (Fig. 5). Some studies have suggested increased rotational stability with a pegged glenoid.^{13,20} It is essential that the trial glenoid be well seated and not “rock” (Fig. 6). If a cemented component is used, a third-generation cementing technique is then used to implant the component (Fig. 7). The humeral head prosthesis radius of curvature and thickness is selected based on which size maximizes mobility, stability, and permits tension-free subscapularis closure. In most total shoulder systems, the humeral head’s radius of curvature is less than the glenoid to minimize constraint. This mismatch allows the humeral head to move anteroposterior and superior-inferior without being constrained.¹⁶ When testing stability and motion start with the head seated in the glenoid component, then translate the head anterior, posterior, and inferior. Closure of the subscapularis should be tension free, and allow 50% anterior, posterior, and inferior translation on the glenoid, and the ability of the hand to reach the opposite axilla. If the subscapularis is too tight, the capsule can be excised by careful dissection from the posterior aspect of the muscle, which allows a gain of about 1 cm of length. In addition, the superior edge of the subscapularis can be recessed with an oblique cut, which can give an additional 7 mm of length.²⁰ If the subscapularis has been taken off the bone, it can

be reattached in a more medial location. Each centimeter of medialization provides approximately 20 degrees of increased external rotation.¹³

Closure

The subscapularis is then repaired anatomically to the remaining stump on the lesser tuberosity with a numbers 2 and 5 ethibond, or fiberwire with the arm internally rotated. If the tendon is of questionable quality, the repair can be augmented with a suture tape in a figure-of-8 technique. If the tissue is amenable, the fascia overlying the deltopectoral interval can be repaired with absorbable suture. A drain is placed in the space deep to the deltoid and can either be brought out of the wound or out of a separate exit through the anterior deltoid. A watertight skin closure is carried out with a nonabsorbable running subcuticular stitch.

COMPLICATIONS DURING EXPOSURE

Perioperative complications are infrequent but occur during glenoid exposure. Perforation or fracture of the glenoid face or neck is possible as a result of drilling or broaching. If this occurs, the defect can be augmented with corticocancellous grafts from the humeral head. These can be fixed either with screws or suture anchors with drill holes.²⁰ Acute intra-articular infections, within the first 6 weeks, can be treated with irrigation and debridement, and intravenous antibiotics with the retention of the implants. If the infection does not begin to resolve with multiple debridements, then implant removal should be carried out with a staged reconstruction.²⁰

SUMMARY

Total shoulder arthroplasty is a good procedure with a successful long-term record. The indications for resurfacing the glenoid include pain reduction, increased stability in the setting of minor glenoid wear, and the potential for improved motion and strength. The glenoid should not be resurfaced in



FIGURE 7. The glenoid component is then cemented in place with excess cement carefully removed.

the setting of a deficient rotator cuff, significant bone loss, or a young active patient because of the increased failure rates in these populations. The key steps to successfully resurface the glenoid include adequate muscle relaxation by anesthesia, complete release of any contractures, especially of the subscapularis and of any subacromial bursal adhesions, precise placement of the component as aided by good exposure to the glenoid, and correct balancing of the soft tissues throughout.

REFERENCES

1. Torchia ME, Cofield RH, Settergren CR. Total shoulder arthroplasty with the Neer prosthesis: long-term results. *J Shoulder Elbow Surg.* 1997;6:495–505.
2. Wirth MA, Rockwood CA Jr. Complications of shoulder arthroplasty. *Clin Orthop Relat Res.* 1994;307:47–69.
3. Gartsman GM, Roddey TS, Hammerman SM. Shoulder arthroplasty with or without resurfacing of the glenoid in patients who have osteoarthritis. *J Bone Joint Surg Am.* 2000;82:26–34.
4. Brems JJ. Arthritis of dislocation. *Orthop Clin North Am.* 1998;29:453–466.
5. Sperling JW, Cofield RH. Revision total shoulder arthroplasty for the treatment of glenoid arthrosis. *J Bone Joint Surg Am.* 1998;80:860–867.
6. Baumgarten KM, Lashgari CJ, Yamaguchi K. Glenoid resurfacing in shoulder arthroplasty: indications and contraindications. *Instr Course Lect.* 2004;53:3–11.
7. Rodosky MW, Bigliani LU. Indications for glenoid resurfacing in shoulder arthroplasty. *J Shoulder Elbow Surg.* 1996;5:231–248.
8. Boyd AD Jr, Thomas WH, Scott RD, et al. Total shoulder arthroplasty versus hemiarthroplasty. Indications for glenoid resurfacing. *J Arthroplasty.* 1990;5:329–336.
9. Franklin JL, Barrett WP, Jackins SE, et al. Glenoid loosening in total shoulder arthroplasty. Association with rotator cuff deficiency. *J Arthroplasty.* 1988;3:39–46.
10. Connor P, Bigliani LU. Prosthetic replacement for osteoarthritis: hemiarthroplasty versus total shoulder replacement. *Semin Arthroplasty.* 1997;8:268–277.
11. Sperling JW, Cofield RH, Rowland CM. Neer hemiarthroplasty and Neer total shoulder arthroplasty in patients fifty years old or less. Long-term results. *J Bone Joint Surg Am.* 1998;80:464–473.
12. Bell RH, Noble JS. The management of significant glenoid deficiency in total shoulder arthroplasty. *J Shoulder Elbow Surg.* 2000;9:248–256.
13. Wright TW. The glenoid component: preparation and insertion. In: Zuckerman JD. 1st ed. *Advanced Reconstruction: Shoulder.* Rosemont, IL: American Academy of Orthopaedic Surgeons; 2007:507–516.
14. Ibarra C, Dines DM, McLaughlin JA. Glenoid replacement in total shoulder arthroplasty. *Orthop Clin North Am.* 1998;29:403–413.
15. Post M. Operative treatment of degenerative and arthritic diseases of the glenohumeral joint. In: Cooke D, ed. *The Shoulder: Operative Technique.* Baltimore: Williams & Wilkins; 1998:73–131.
16. Zuckerman J, Sajadi K. Approach and exposure for primary total shoulder arthroplasty: glenoid and proximal humerus. In: Zuckerman JD. 1st ed. *Advanced Reconstruction: Shoulder.* Rosemont, IL: American Academy of Orthopaedic Surgeons; 2007:497–504.
17. Weber SC, Jain R. Scalene regional anesthesia for shoulder surgery in a community setting: an assessment of risk. *J Bone Joint Surg Am.* 2002;84-A:775–779.
18. Conn RA, Cofield RH, Byer DE, et al. Interscalene block anesthesia for shoulder surgery. *Clin Orthop Relat Res.* 1987;216:94–98.
19. Bishop JY, Sprague M, Gelber J, et al. Interscalene regional anesthesia for shoulder surgery. *J Bone Joint Surg Am.* 2005;87:974–979.
20. Hayes PRL, Flatow EL. Steps for reliable glenoid exposure and preparation in shoulder arthroplasty. *Tech Shoulder Elbow Surg.* 2000;1:209–219.